

# **Computed Tomography (CT) Study on the effects of age changes and sex differences on morphology of hyoid bone** (from age 20 years to more than 60 years old)

(Hebatullah Al-Sayed Abdel-Hameed Hassan , Talaat Mostafa Mohamed,  
Eman Ali Elsayed Elbanna , Nehal Fahmy Shaheen)

## **Abstract**

The Hyoid bone is a small (mostly U-shaped) bone located in the front of neck at level of 3<sup>rd</sup> cervical vertebra attached to several important ligaments and muscles. It's involved in breathing , chewing , swallowing and speech . In our study we aimed at determining age and sex differences regarding morphology and position of hyoid bone using 3D and 2D CT. Our study was carried out retrospectively on head and neck CT scan films of 120 normal living Egyptian individuals which were done in Benha University hospitals .These individuals divided into 3 age groups, each one contained 40 individuals. Each group contained 20 males and 20 females of the same age group. Through these CT films, some measurements were taken which were: degree of fusion between hyoid body and greater horn, length and height of hyoid bone body, length of greater horn, angle between body and greater horn, hyoid width, hyoid length, MP.H. (Mandibular plane – hyoid distance) and H.RGn (Hyoid – Retroganthion distance). Different shapes of hyoid bone were recorded and its association with certain sex. The measurements were analyzed statistically in relation to age and sex. We found that there were significant differences between male and female regarding : shape , body length , body height , GH length ,Hyoid width ,Hyoid Length and H.RGn. There were statistically significant differences between age groups regarding fusion , and degree of fusion and body height and MP.H. Finally , we concluded that hyoid bone could be utilized to assign age, sex and race when used in conjunction with other bones of the body . These measurements could also be used to explain etiology of incidence of certain respiratory diseases.

## **Keywords:**

Hyoid bone morphology – Hyoid measurements – Hyoid Fusion – Hyoid shapes – 3D CT – Forensic investigation – clinical significance.

## **Introduction:**

The name hyoid means shaped like lower case Greek letter Epsilon  $\upsilon$  (1). The hyoid bone is located in front of the cervical spine (the bones of the neck). It is located at the level of the 3<sup>rd</sup> cervical vertebra. It attaches by means of ligaments, to a projection of bone called the styloid process, which extends from the temporal bone. The hyoid bone is firmly secured to the thyroid cartilage (22).

At birth, the hyoid bone consists of a central body and pairs of lesser and greater cornua. Fusion of the greater cornua with the body normally occurs in adulthood, but may not occur at all in some individuals (9). Widely accepted morphological classification does not exist. It is commonly classified into two types, hyperbolic (U-type) and parabolic (V-type), but there is also alternative classification model that recognizes five bone types: D-, B-, H-, U- and V-type (14),(16).

The hyoid bone body develops from the second and third pharyngeal arch cartilages (6). The second pharyngeal arch forms the lesser horn (cornu) and the upper body of the hyoid, while the greater horn (cornu) and the lower portion of the body derive from the third pharyngeal arch. This embryonic development of the hyoid remains controversial (11).

Even though the hyoid bone is an important structure, it has not received the attention that it deserves. It participates in the function of speech, respiration, mastication, and swallowing, as well as maintaining the patency of the airway between the oropharynx and the tracheal rings (2).

Establishing the identity of unidentified human remains is crucial in forensic investigations. Sex determination from an assessment of the skeletal remains is a priority as is usually used as a foundation for the estimation of other biological profiles (27). Torimitsu et al. (2017) further encourages researchers to conduct more studies on the hyoid bone and its potential in determining age, sex, race and cause of death, within different population groups (23). To estimate sex from hyoid bones, metric measurements have been used alone, or in combination with morphologic characteristics (25).

Three-dimensional (3D) imaging has the combined advantages of manual measurement of bone and 2D imaging and permits assessment of hyoid

bone shape and dimensions as well as its growth relative to other structures during the course of development. Computed tomography (CT) scans are effective (4)

The purpose of this study was to point to the forensic significance of hyoid bone (identification of age and sex) by determining changes implied by both in the morphology of hyoid bone including : Degree of fusion between body and greater horn of it , Dimensions of its parts , Differences in shape of it between males and females. Also , to detect changes in the position of hyoid bone with age in both sexes ( Thus we can explain why swallowing defects occurs in a certain age and sex as well as the clinical significance of this bone).

### **Subjects and Methods :**

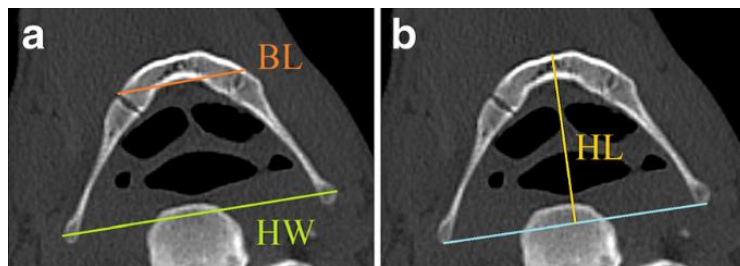
Our study was carried out retrospectively on head and neck CT scan films of 120 normal living Egyptian individuals. Axial and lateral view images of head and neck 3D CT and 2D CT were randomly chosen from those coming to Benha University Hospital of known birth date and sex. They were not exposed to unnecessary radiation and were not administered drugs because all the selected patients had undergone mandatory head and neck CT examination for other reasons.

These individuals were divided into 3 age groups, each one contained 40 individuals. Group 1: from 20 to 39 years old, Group 2: from 40 to 59 years old and Group 3: from 60 years old onwards. Each group contained 20 males and 20 females of the same age group.

Through these CT films, some measurements of hyoid bone were taken using RadiAnt DICOM viewer 4.2.1 (32 bits) program. First of all was degree of fusion between hyoid body and greater horn. Each group has been ranked into 3 categories according to the degree of fusion: (rank 1) : Bilateral non-fusion ( no fusion observed at the connection area) (13) , (rank 2) : Unilateral (any hyoid bone with fusion on only one side was given a ranking of “2”) (10) or partial fusion ( ossification commenced at the connection area but there was linear junction fusion alone) (13) and (rank 3) : Bilateral fusion (complete ossification without a trace of a fusion line) (13).

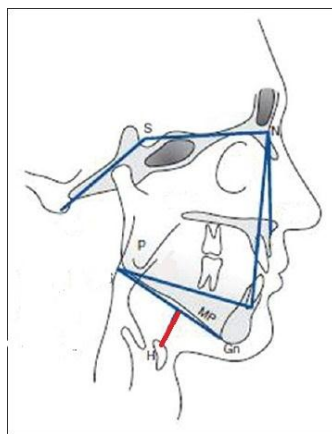
The other measurements were : \*Body length "BL" of hyoid bone (Linear distance between the most lateral edges of the hyoid body(27)) and \*Body height "BH" of hyoid bone (Distance between the upper and lower margins of the body (22)), \*Greater horn length "GHL" (22) (mean value for 2 sides) , \* Angle between body and greater horn (13) (mean value for 2 sides) , \*Hyoid Width "HW" (the distance between midpoints of distal ends of greater horns (25)) ,

\*Hyoid Length "HL" (Perpendicular distance from the midpoint of a line drawn between the distal ends of the right and left greater cornua to the midpoint of the posterior aspect of the hyoid body (12))

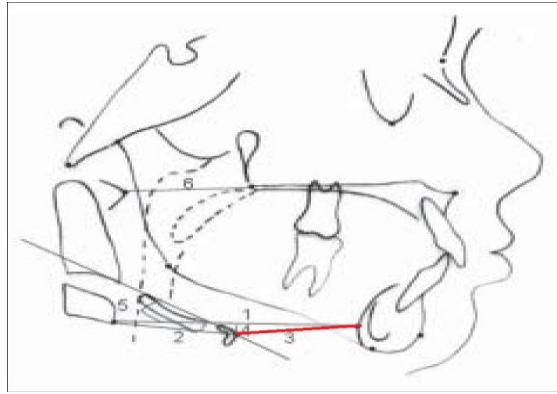


**Figure (1) - Different measurements of hyoid bone**  
:BL=Body length , HW = Hyoid width ,HL=Hyoid length (27)

\* MP.H. (Mandibular plane – hyoid : vertical distance between mandible and hyoid (15)) \*H.RGn (Hyoid – Retroganthion : anteroposterior distance from the hyoid to the most dorsal point of the mandibular symphysis (18)).



**Figure (2) - Cephalometric linear and angles measures of the Hyoid Triangle** \* the one used here is MP.H.(mandibular plane –hyoid)  
"red line (15)



**Figure (3) - different cephalometric measures** \*The one used here is (3)  
 = H.RGn : Hyoid retrognathion distance "**red line**" (8)

Lastly , different shapes of hyoid bone were recorded (U , V and boat shaped (16,20,14)) and its association with certain sex.

These morphometric parameters were then the measurements were analyzed statistically in relation to age and sex.

### **Data analysis**

The clinical data were recorded on a report form. These data were tabulated and analyzed using the computer program SPSS (Statistical package for social science) version 26 to obtain. Descriptive data were calculated for the data in the form of: 1-Mean and standard deviation ( $\pm SD$ ). for quantitative data.2-Frequency and distribution for qualitative data (3).

*Analytical statistics:* In the statistical comparison between the different groups, the significance of difference was tested using one of the following tests : \**Student's t-test* which was used to compare mean of two groups of quantitative data. Statistical analysis was performed using IBM\_ SPSS\_ Statistics 18 software with a 5 % threshold of significance Measurements of males and females (in the whole sample) were compared using student's t test (6).\**ANOVA test* (F value) which is used to compare mean of more than two groups of quantitative data. We also tested the allometry, i.e., the relationship between size and shape using ANOVA (6).\**Inter-group* comparison of categorical data was performed by using chi square test ( $X^2$ -value) or Fischer exact test (*FET*).

\**Correlation coefficient*:- to find relationships between variables.

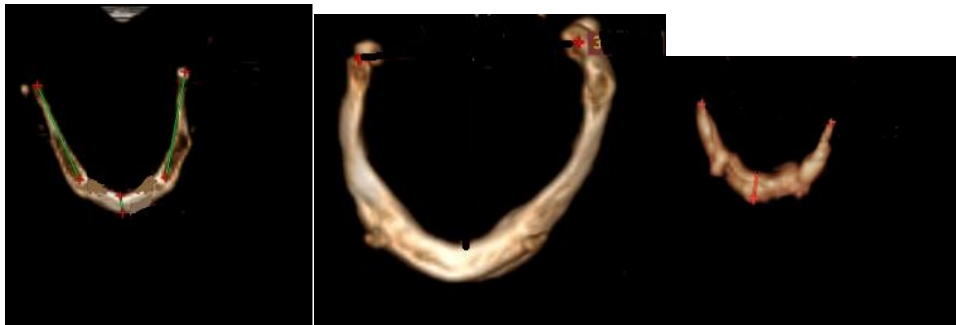
$P$  value  $<0.05$  was considered statistically significant (\*) while  $>0.05$  statistically insignificant  $P$  value  $<0.01$  was considered highly significant (\*\*) in all analyses

## Results :

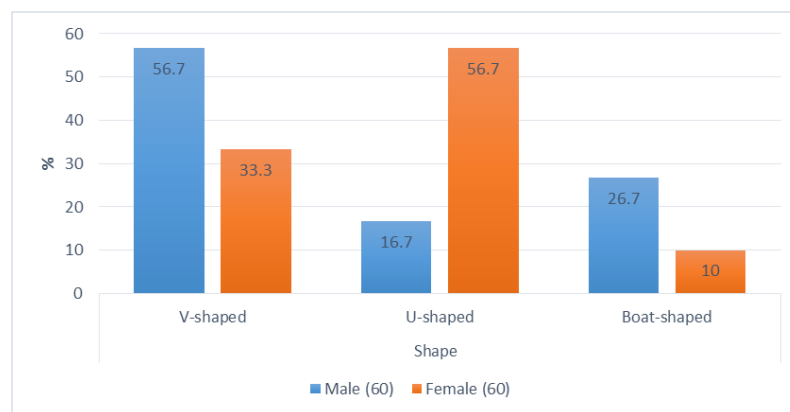
After recording and comparing the measurements between males and females and also between age groups , the following were found :

**-Shape :** There were 10 U-shaped , 34 V –shaped and 16 boat shaped among male groups. However , there were 34 U-shaped , 20 V-shaped and 6 boat shaped among female groups.

This difference was statistically significant with  $P$ -value  $<0.001$ . Among age groups: In age group 1 , there were 16 V-shaped , 16 U- shaped and 8 boat-shaped hyoid bones. In age group 2 , there were 20 V-shaped , 14 U-shaped and 6 boat-shaped hyoid bones. In age group 3 , there were 18 V-shaped , 14 U-shaped and 8 boat-shaped hyoid bones. The difference between age groups was insignificant statistically as  $P$ -value was 0.9 .

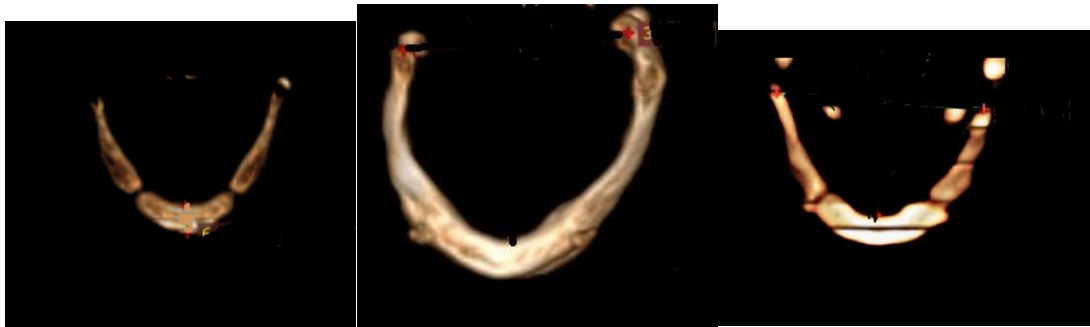

**Fig.(4)** From left to right : U-shaped hyoid (female , 52 years) – V-shaped hyoid ( male , 55 years) – Boat-shaped hyoid (female , 75 years)

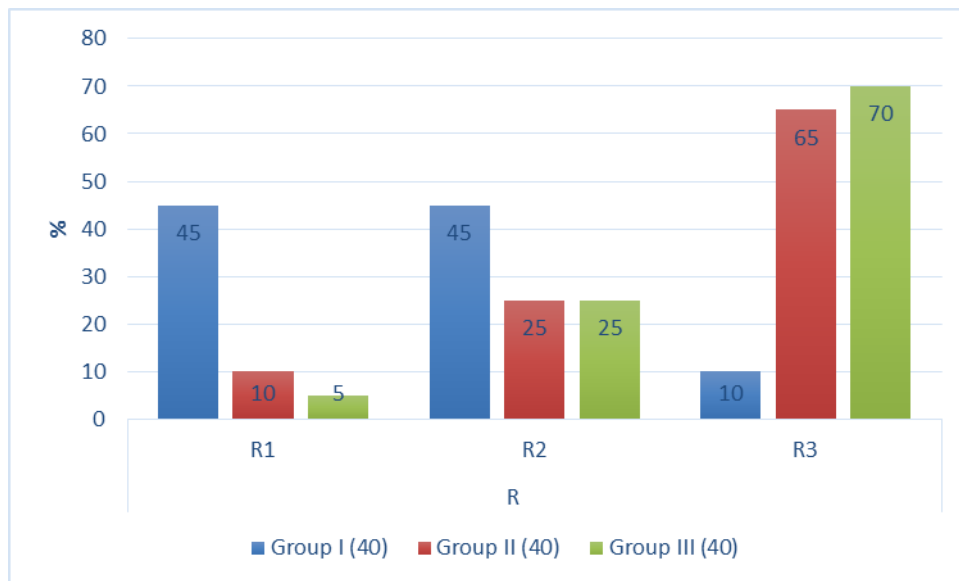


**chart (1):** Bar chart shows comparison between male and female according to shape

**-Fusion :** There were 14 cases in rank 1 , 18 cases in rank 2 and 28 cases in rank 3 among male groups. There were 10 cases in rank 1, 20 cases in rank 2 and 30 cases in rank 3 among female groups. The difference was statistically non-significant with P-value 0.66. However, In age group 1, there were 18 R1 , 18 R2 and 4 R3 hyoid bones. In age group 2, there were 36 fused and 4 non-fused hyoid bones. In age group 3, there were 38 fused and 2 non-fused hyoid bones. The difference between age groups was highly significant statistically as P-value was <0.001.



**Figure (5)** From left to right: *Non-fusion R1 (male , 23 years) – complete fusion R3 ( male , 55 years) – Partial fusion R2 (female , 30 years)*



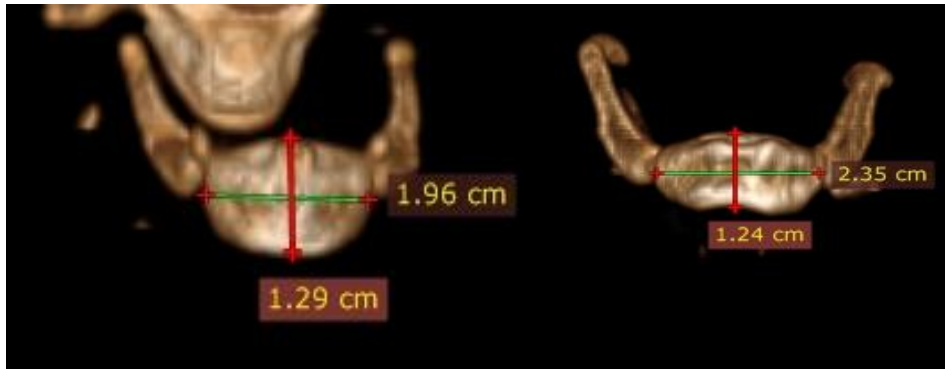
**Chart (2):** Bar chart shows comparison between different age groups according to Rank of fusion

**-Body length (BL)** of hyoid bone: The mean was 24.10 mm among male groups and 19.30 mm among female groups. The difference was statistically significant with P value <0.001. Among age groups : The mean values of BL were 20.5 mm in age group1 , 22.5 mm in age group2

and 22.1 mm in age group 3. The difference between age groups was statistically insignificant as P-value was 0.098.

**-Body height (BH)** of hyoid bone: The mean was 12.7 mm among male groups and 10.1 mm among female groups. The difference was statistically significant with P value <0.001.

Also, the mean value of BH was 12.05 mm in age group 1, 11.7 mm in age group 2 and 10.5 mm in age group 3. The difference was considered statistically significant as P value was 0.015.

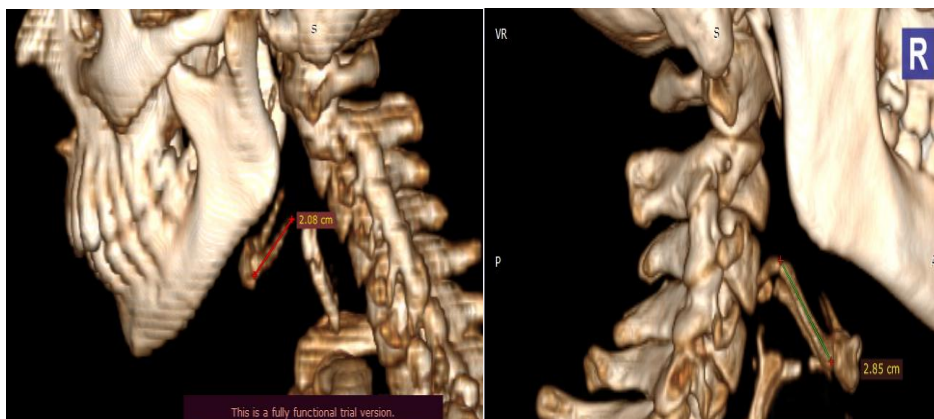


**Figure (6)** BL : green arrow , BH : red arrow

Left : BL = 19.6 mm , BH= 12.9 mm (female , 22 years)

Right : BL= 23.5 mm , BH= 12,4 mm ( male , 29 years)

**-Greater horn length (GHL):** The mean was 27 mm among male groups and 23mm among female groups. The difference was statistically significant with P value <0.001. However, the mean value of GHL was 24.7 mm in age group 1, 26.05 mm in age group 2 and 24.6 m in age group 3. The difference was statistically insignificant as P value was 0.3.

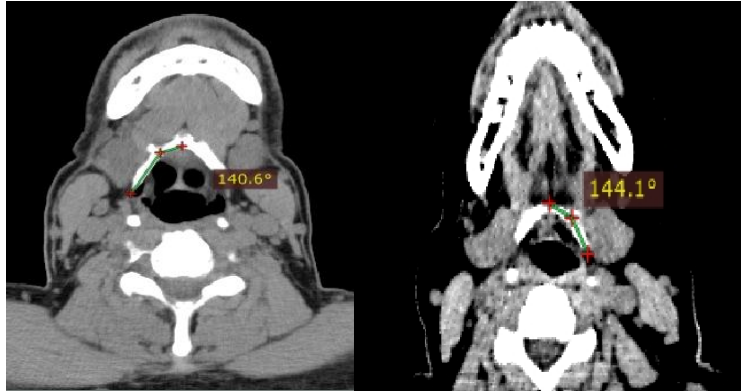


**Figure (7)** Left : GHL (red line) = 20.1 mm (Female , 40 years )

Right : GHL (green line) = 28.5 mm (male , 29 years)



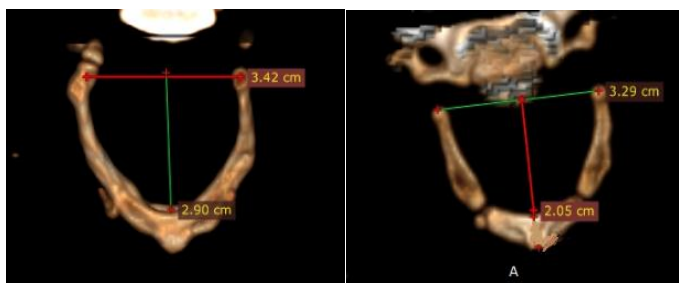
- **Angle between body and greater horn:** The mean was 147.77° among male groups and 149.77° among female groups. The difference was statistically not significant with P-value 0.3. Among age groups, the mean value of the angle was 148.25° in age group 1, 150.1° in age group 2 and 147.9 ° in age group 3. .The difference was statistically insignificant as P value was 0.62.



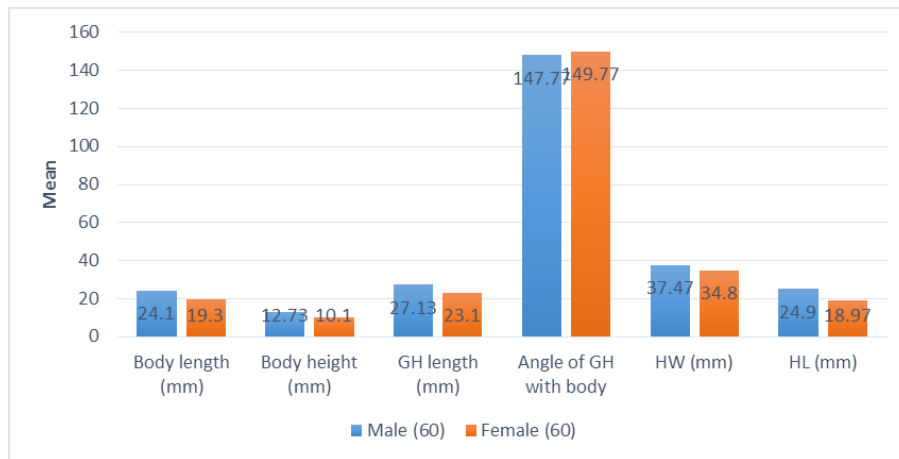
**Figure (8)** Left : angle = 140.6° ( male , 55 years ) , Right : angle = 144.1° (female, 55 years)

-**Hyoid width:** The mean was 37.47 mm among male groups and 34.8 mm among female groups. The difference was statistically significant with P value <0.001. The mean value of HW was 36.8 mm in age group 1 , 36.1 mm in age group 2 and 35.5 mm in age group 3..

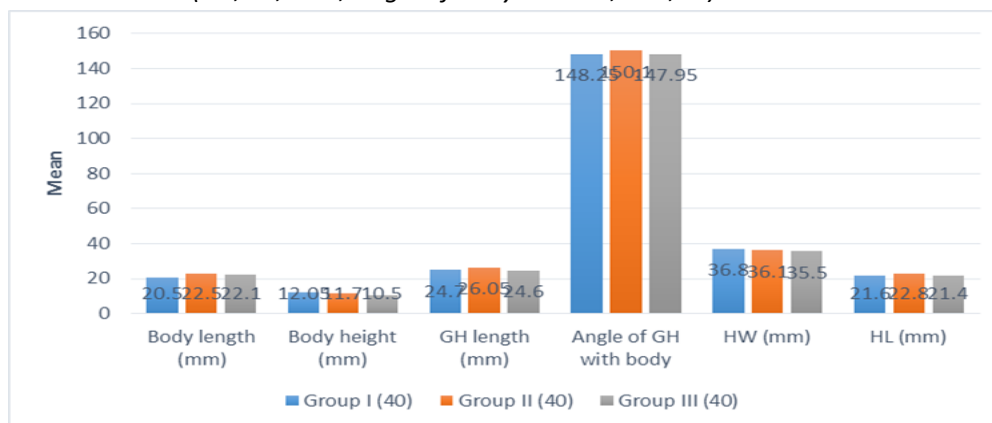
-**Hyoid length:** The mean was 24.9 mm among male groups and 18.9 m among female groups. The difference was statistically significant with P value <0.001.The difference was statistically insignificant with P value 0.31. The mean value of HL was 21.6 mm in age group 1 , 22.8 mm in age group 2 and 21.4 mm in age group 3. The difference was statistically insignificant with P value 0.44.



**Figure (9)** Left : HW (red arrow)=34 mm , HL(green arrow)=29mm (male , 55 years) – Right : HW (green arrow) =32.9 mm , HL (red arrow) = 21 mm ( female , 22 years)



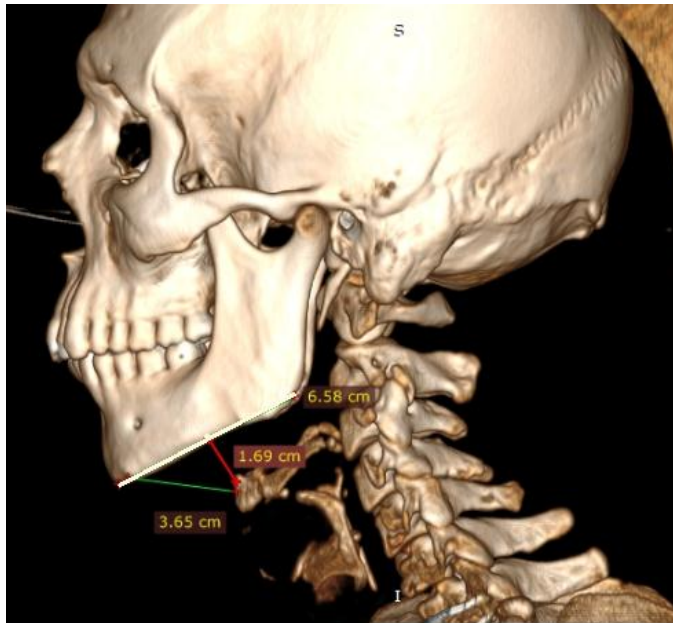
**chart (3):** Bar chart shows comparison between male and female according to measurements. (BH, BL, GHL, angle of body and GH, HW, HL)



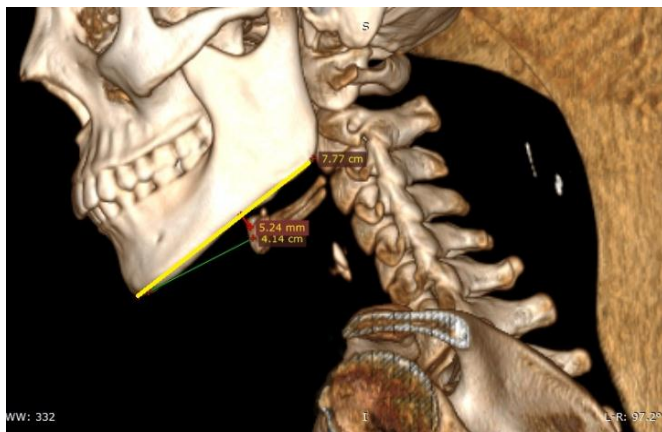
**chart (4):** Bar chart shows comparison between age groups according to measurements. (BH, BL, GHL, angle of body and GH, HW, HL)

**-Mandibular plane – Hyoid (MP.H.) distance:** The mean was 0.9 cm among male groups and 0.8 cm among female groups. The difference was statistically non-significant with P-value 0.44. The mean value of MP.H. was 0.7 cm in age group 1, 0.96 cm in age group 2 and 0.93 cm in age group 3. The difference was statistically significant with P value 0.29.

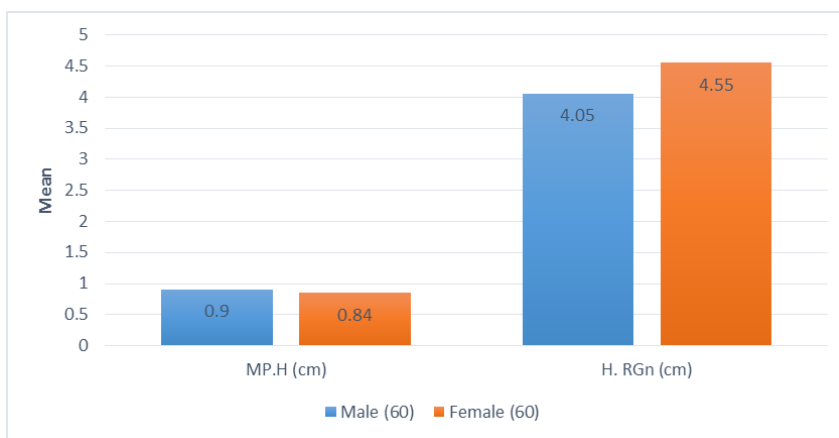
**-Hyoid-Retroganthion (H.RGn) distance:** The mean was 4.05 cm among male groups and 4.55 cm among female groups. The difference was statistically significant with P value <0.001. The mean was 4.39 cm in age group 1, 4.37 cm in age group 2 and 4.15 cm in age group 3. The difference was statistically insignificant with P value 0.2.



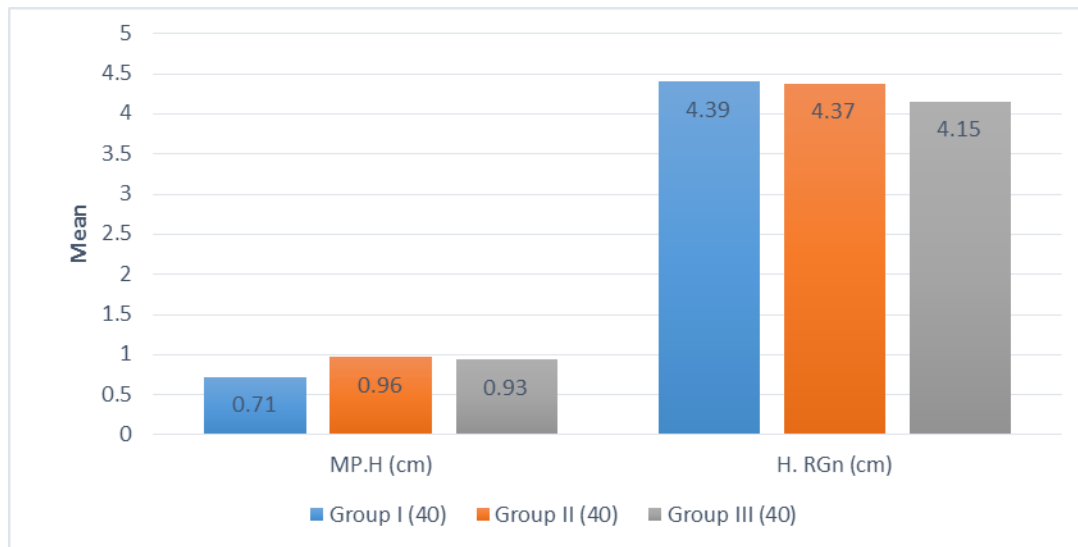
**Figure (10) : MP.H (red line)= 1.69 cm , H.RGn (green line) = 3.65 cm , (male , 28 years)**



**Figure (11) : MP.H.(red line) = 0.52 cm , H.RGn (green line) = 4.14 cm (female , 22 years)**



**chart (5) : Bar chart shows comparison between male and female according to MP.H and H.RGn**



**Chart (6) :** Bar chart shows comparison between age groups according to MP.H and H.RGn

After **statistical analysis** of the results, we found that there were significant differences between male and female regarding: shape, body length, body height, GH length, Hyoid width, Hyoid Length and H.RGn. However, there were insignificant differences between male and female regarding fusion, degree of fusion, angle of GH with body and MP.H.

As for age, there were statistically significant differences between age groups regarding fusion, and degree of fusion and body height and MP.H. However, the differences were statistically non-significant between age groups regarding shape, body length, GH length, angle of GH with body, HW, HL and H.RGn .

Specific correlations were found. There was inverse significant relationship between age and body height in all (i.e. the body height in all samples decreased as age increase. Among male groups, there was a direct significant relationship between age and both of body length and MP.H. Among female groups, there was an inverse significant relationship between age and both of Body height and angle of GH with body.

**(N.B.)**  $P$  value  $<0.05$  was considered statistically significant (\*) while  $>0.05$  statistically insignificant  $P$  value  $<0.01$  was considered highly significant (\*\*) in all results.

All Findings can be summarized in the following table: **(Table 1)**

	All males	All females	Age group 1	Age group 2	Age group 3	Notes
V –shaped	34	20	16	20	18	More in males
U-shaped	10	34	16	14	14	More in Females
Boat- shaped	16	6	8	6	8	More in males
Non-fused R1	14	10	18	4	2	Fusion increases with age
Fused R2	18	20	18	10	10	Same with above
Fused R3	28	30	4	26	28	Same with above
BL	24 mm	19 mm	20 mm	22.5 mm	22 mm	Values are higher & increase with age in males
BH	12 mm	10 mm	12 mm	11 mm	10 mm	Values are higher in males , decrease with age in all (especially females)
GHL	27 mm	23 mm	24 mm	26 mm	24 mm	Values are higher in males
Angle Body-GH	147°	149°	148°	150°	148°	Decreases with age in females
HW	37 mm	34 mm	36 mm	36 mm	35 mm	Values are higher in males
HL	24 mm	18 mm	21 mm	22 mm	21 mm	Values are higher in males
MP.H	0.9 cm	0.8 cm	0.7 cm	0.96 cm	0.93 cm	Increases with age in males
H.RGn	4 cm	4.55 cm	4.4 cm	4.4 cm	4.2 cm	Values are higher in females

The measurements presented some variations in comparison with previous studies. The different values could be due to racial, ethnic and regional variations. This data can be used for demographic studies, comparative studies among different population groups and forensic cases.

### **Discussion:**

The present study was done on 120 individuals. We have recorded the shapes of hyoid bones, fusion of greater horn and body of hyoid bone, rank of fusion (R), body length (BL) and body height of hyoid bone (BH), greater horn length (GHL), angle of greater horn with the body (mean of 2 sides), hyoid width (HW), hyoid length (HL), mandibular plane – hyoid (MP.H) distance and hyoid – retrognathion (H.RGn) distance in addition to recording age and sex of selected individuals. We also compared the obtained results between age groups (3 groups where age was between 20 to more than 60 years) and also compared the results between males and females.

Regarding the shape, 3 shapes were found of which the V-shaped (56%) and boat – shaped hyoid bones (26%) were more common in male groups and the U-shaped hyoid bones (57%) was more common in female groups. These results were nearly similar to a study which was done by **Priya and Kumari (2016) (20)** who agreed with our results as they found that V shape was more common (36.16 %) in adult males when compared to U shaped hyoid bone (35.29%) in adult females. Boat – shaped was found in both sexes but in more in males (7%) ..

As for fusion of greater horn and body and its rank, three observations were detected in our current study:

- First, fusion degree increased with age in both males and females. Among males in age group 1, there were only 6 fused cases but in age group 3, all 20 were fused whether unilaterally or bilaterally. Also in females in age group 1, there were 16 fused cases but in age group 3, 18 cases were fused whether unilaterally or bilaterally. This was agreed by **Ito et al., (2012) (13)** in a study on 300 Japanese cases in which they stated that ossification increased with age.
- Second, our study also showed that among females, fusion started earlier below age of 40 and the total number of fused hyoid bones

(unilaterally or bilaterally) was higher. At the same time among males, bilateral fusion was more in middle age group and this showed that the percentage of bilateral fusion was not strictly increasing by age in males and it was completed earlier. **Fisher et al., (2016) (9)** reported - differently from our study -that there was no significant association between fusion and sex but they agreed with our findings that bilateral fusion was not strictly increasing by age.

- Lastly , Our study reported an unexpected finding that there were 2 cases of females - whose age were 75 and 64 years old - in age group 3 had bilateral non-fused hyoids. **Hak et al., (2007) (12)** mentioned a similar unexpected unexplained finding that one female case aged 63y had bilateral non fusion of the greater cornu to the body and another female aged 65y had unilateral right non-fusion.

Regarding body length of hyoid bone (BL), in our study we found that BL was larger in males than females. As for age groups, the relationship between age and hyoid body length was insignificant in females while there was direct relationship between age and body length in males. These findings were agreed by **Torimitsu et al., (2017) (27)**, **Soltani et al., (2017) (25)** and **Hak et al., (2007) (12)**.

As for body height of hyoid bone (BH), our study showed that it was larger in males than females. In age groups, the body height decreased with age (inverse relationship). These results were approved by **Priya and Ranzeetha (2015) (21)** and **Mostafa (2017) (19)** also their values were nearly similar to ours too.

The mean greater horn length "GHL" was also higher in males than females but among age groups, the relationship between it and age couldn't be determined neither for males or females. **Priya and Ranzeetha (2015) (21)** agreed with our study that GHL values were more in males than females but differently they stated that GHL increased with age in males and not in females.

The mean value of angle between body of hyoid and greater horn was higher in females but, the difference was statistically insignificant between males and females. However, there was significant inverse

relationship between age and this angle in female age groups only. **Ito et al., (2012) (13)** reported similar results.

As for hyoid width (HW), male values were higher which was highly significant statistically. For age groups, HW was almost similar among them, so age wasn't correlated with HW neither in males nor females. Our results were agreed by **Lekšan et al., (2005) (20)**, **Torimitsu et al., (2017) (44)** and **Fakhry et al., (2013) (8)**.

Hyoid length (HL) as measured in this study was larger in males than females with highly significant relationship with sex but age didn't affect it. **Hak et al., (2007) (12)** had the same definition for HL and had mentioned very similar values as our study.

Mandibular plane – hyoid plane (MP.H) as measured here had different correlation. The difference between males and females wasn't statistically significant. However; age had direct relationship with MP.H. among male age groups only. This can explained high occurrence of aspiration – swallowing defect - in old aged males. These results were approved by **Feng et al.,(2014) (7)**.

Lastly, hyoid – retroganthion (H.RGn) distance had higher values in females than males and the difference was statistically significant but, the differences were not significant among age groups. Similar results were found by **Ferraz et al., (2015) (8)**.

### **Conclusion:**

Although the hyoid bone is small and fragile, when used in conjunction with other bones of the body, this bone may be utilized to assign age, sex and race. Most of the readings of above parameters were greater in males than in females and some of them showed increase with advancement of age while few showed decrease with age mostly in a certain sex. In most of the parameters, there was a clear cut demarcation between the value of male and female bone. The present study indicates that the sex and age group can be determined with much more accuracy by taking the discriminant analysis of the different parameters of hyoid bone but the accuracy is not satisfactory if only one parameter is taken. In addition to that, measured distances between hyoid bone and other points or planes in body as retroganthion and mandibular plane showed great differences implied by age and sex. This



explains why certain disorders as aspiration and other respiratory disorders occur more frequently in certain sex or certain age.

### **Recommendations:**

The present study is considered as a preliminary study due to the small number of cases which were available during the duration of the study. Further studies on hyoid bones in a larger Egyptian population sample would be necessary. More additional information is needed about the age and sex variation of the lesser cornu because they may be of worthy use in forensic investigations. Comparison among studies from different races is recommended. Also, more studies recording correlation between Cephalometric measurements which include hyoid bone as (MP.H. and H.RGn) and occurrence or severity of respiratory disorders are highly recommended.

### **References:**

1. **Anderson D.M., Novak P.D. , Keith J. , Eliot M.A. , Tannian P. , Van Pelt L. and Stave S. (2012)** :Dorland's illustrated medical dictionary , USA , Elsevier . P.885
2. **Auvenshine RC and Pettit NJ (2020)** , The hyoid bone: an overview. *Cranio.*;38(1):6-14
3. **Brink D. (2010)** : Essentials of statistics , ventus publishing ABS : Frederiksberg , Denmark 2<sup>nd</sup> ed : 1-103
4. **Cotter M. , Whyns B.J. , Kelly M.P. , Doherty B.M. , Gentry L.R., Bersu E.T. and Vorperian H.K. (2015)** : Hyoid Bone Development: An Assessment of Optimal CT Scanner Parameters and Three-Dimensional Volume Rendering Techniques" *The anatomical record* "298:1408–1415
5. **de Bakker B.S., de Bakker H.M., Soerdjbalie- Maikoe V. and Dijkers F.G. (2018)** : Hyoid–Larynx Complex Development Revisited . *Laryngoscope* 128, P:1829-1834.
6. **Fakhry N., Puymeraill L., Michel J., Santini L., Lebreton-Chakour C., Robert D., Giovanni A., Adalian P. and Dessi P. (2013)**. Analysis of Hyoid Bone Using 3D Geometric Morphometrics: An Anatomical Study and Discussion of Potential Clinical Implications. *Dysphagia*. **28(3)** , Springer Science+Business Media New York
7. **Feng X., Todd T., Hu Y., Lintzenich C.R., Carr J.J., Browne J.D., Kritchevsky S.B. and Butler S.G. (2014)**: Age-related changes of

hyoid bone position in healthy older adults with aspiration.  
Laryngoscope ;124(6):E231-6.

8. **Ferraz M.J.P.C, Nouer D.F., Bérzin F., Sousa M.A. and Romano F.(2015)** Cephalometric appraisal of the hyoid triangle in brazilian people of Piracicaba's region. Braz. J. Oral Sci. [Internet].;5(17):1001-6.
9. **Fisher E. , Austin D. , Werner H. , Chuang Y.J. , Bersu E. and Vorperian H.K. (2016)** : Hyoid bone fusion and bone density across the lifespan: prediction of age and sex " Forensic Sci Med Pathol " , Ch:12 , P:146–157
10. **Fisher E. and Vorperian H.K. ( 2014)** : Development of the Hyoid Bone: Fusion and Bone Density , Vocal Tract Development Lab, Waisman Center, University of Wisconsin – Madison .
11. **Genta P.R., Schorr F., Eckert D.J., Gebrim E., Kayamori F., Moriya H.T., Malhotra A. and Lorenzi-Filho G. (2014)** : Upper airway collapsibility is associated with obesity and hyoid position. Sleep. 1;37(10):1673-8
12. **Hak S.A.G.E., Dakroory S.A.E., Hawary A.A.E. and Alghazally A.M. (2007)**, sexual dimorphism of the Hyoid bone. A preliminary study, **Mansoura J. Forensic Med. Clin. Toxicol. Vol. XV, No. 1, p: 17-31.**
13. **Ito K. , Ando S. , Akiba N. ,Uno K. , Okuyama Y. Moriguchi H. , Yoshikawa K. , Takahashi T. and Shimada M. ( 2012 ):** Morphological study of the human hyoid bone with three-dimensional CT images – Gender difference and age related changes "Okajimas Folia Anat. Jpn., 89(3): 83 – 92
14. **Kopuz, C., & Ortug, G. (2016).** Morfología Variable del Hueso Hioides en una Población de Anatolia: Consecuencias Clínicas-Un Estudio Cadavérico. *International Journal of Morphology*, 34(4), 1396-1403.
15. **Kumari P., Roy S.K., Roy I.D., Rajput A.K., Prasanna Kumar M.P., Datana S. and Rahman S. (2016):** Changes in posterior airway space and mandibular plane hyoid distance following mandibular advancement DO. Ann Maxillofac Surg.;6(2):182-189.
16. **Lekšan, I., Marcikić, M., Nikolić, V., Radić, R., and Selthofer, R. (2005).** Morphological classification and sexual dimorphism of hyoid bone: new approach. *Collegium antropologicum*, 29(1), 237-242.
17. **Moore K.L., Agur A.M.R. and Dalley A.F.(2018)** : Clinically oriented anatomy. Ch :9 (neck) , P: 2220-2.

18. **Mortazavi S, Asghari-Moghaddam H, Dehghani M, Aboutorabzade M, Yaloodbardan B, Tohidi E and Hoseini-Zarch SH. (2018):** Hyoid bone position in different facial skeletal patterns. *J Clin Exp Dent*;10(4):e346-e351.
19. **Mostafa S.M. (2017) :** Estimation of Sex from Hyoid Bone: A Preliminary Study with Medico-Legal Implications . *Ain Shams Journal of Forensic Medicine and Clinical Toxicology ; 29: 1-6.*
20. **Priya K.D.S and Kumari G.A. (2016) :** Sexual dimorphism with the shape of Hyoid bone , international Journal of Anatomy and Research, *Int J Anat Res , ISSN :2321-4287, Vol 4(2):2183-86*
21. **Priya K.D.S. and Ranzeetha D.(2015):** Determination of sex from morphometry of hyoid bone. *Indian Journal of Clinical Anatomy and Physiology, 2(3), pp.157-161.*
22. **Ramagalla A.R. , Sadanandam P. and Rajasree T.K. ( 2014):** Age related metric changes in the hyoid bone " IOSR Journal of Dental and Medical Sciences" e-ISSN: 2279-0853, p-ISSN: 2279-0861. Volume 13, Issue 7 Ver. VI , PP 54-56
23. **Shangase M.O. , Ishwarkumar S. and Pillay P. (2021) :** Morphology and Morphometry of the Hyoid Bone in a Black South African Population. *Int. J. Morphol., 39(1):134-137*
24. **Sinnatamby C.S (2011) :** Last's anatomy regional and applied , osteology of skull and hyoid bone ; 8 : 512.
25. **Soltani S, Aghakhani K and Fallah F. (2017) :** Sex prediction potential of hyoid metric measurements in Iranian adults. *Leg Med (Tokyo) ;25:6-10*
26. **Standring S. , Anand N., Jawaheer G., Tubbs R.S., et al. (2016) :** Gray's Anatomy , Forty-first Edition ,Elsevier ,The Anatomical Basis of Clinical Practice , Ch : 29 , P: 443
27. **Torimitsu, S., Makino, Y., Saitoh, H., Ishii, N., Yajima, D., Inokuchi, G., Motomura, A., Chiba, F., Yamaguchi, R., Hoshioka, Y. and Iwase, H. (2017):** Determination of sex on the basis of hyoid bone measurements in a Japanese population using multidetector computed tomography. *International Journal of Legal Medicine, 132(3), pp.907-914.*
28. **Wineski L.E. (2019) :** Snell's clinical anatomy by regions., Lippincott Williams & Wilkins , Head and Neck ,C 12 , P: 628 .

\*\*\*